

Colonoscopy Report
 Summit Imaging, Inc
 200 NE Mulberry St Suite 102
 Lee's Summit, MO 64086
 (816)246-5777 Fax: (816)525-2028
 www.SummitImaging.net

Name Doe, John
 MRN 6023032 DOB 1-2-1944
 SSN 654-65-1321 Sex Female
 Address
 Phone

Date 4/5/2005 Time 9:47:50 AM Referring Physician Bill Simon, MD

Endoscopist(s) John Smith, MD Assistant(s)

Instrument(s) EC-450HL5 Medication(s) Demerol 50 mg

Reason(s) for Examination Routine screening-average risk Family history of polyp(s)
 Extent of Examination: Cecum

Description of Findings

Informed consent was obtained with the benefits, risks, and alternatives to colonoscopy explained, including the risk of perforation, and the patient agreed to proceed. No contraindications were noted on physical exam. Immediately prior to sedation for endoscopy the patients ASA Classification was Class 1: Healthy patient, no medical problems. The bowel was prepared with PEG solution. The quality of the prep was excellent. Prior to the exam a digital exam was performed and it was unremarkable. The procedure was performed with the patient in the left lateral decubitus position. The instrument was inserted to the cecum. The cecum was identified by the following: the ileo-cecal valve, the appendiceal orifice. In the rectum, the scope was retroflexed and showed no lesions. The patient tolerated the procedure well. There were no complications. The heart rate was normal. The oxygen saturation and skin color were normal. IV conscious sedation was administered under direct supervision of physician. Upon discharge from the endoscopy area, the patient had returned to the level of consciousness noted prior to the procedure.

Endoscopic Diagnoses (see above description)

Colonic polyp(s) (211.3)
 Diverticulosis (562.10)

Procedure CPT Code(s):

Colonoscopy w/ removal of lesions by snare (45385)
 Conscious Sedation w/wo Analgesia; IV/IM/Inhalant (99141)

Therapeutic Procedure(s) Performed

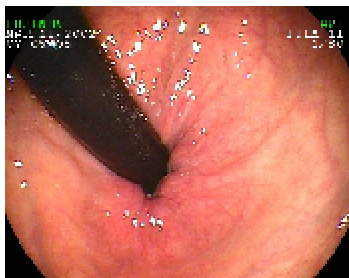Snare Polypectomy Location: distal descending

Specimen(s) Obtained:

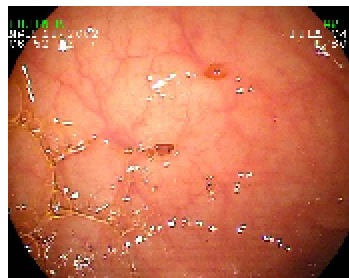Container 1: snare polypectomy X 1 from Distal Descending

Discharge Arrangements:

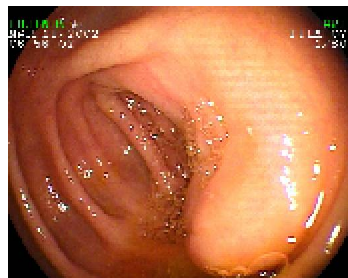The patient was instructed to return to patient's primary care physician in 2 weeks.
 Continue present medications.
 High fiber diet, no nuts, popcorn or seeds.
 Please call office in 1 week for biopsy results.



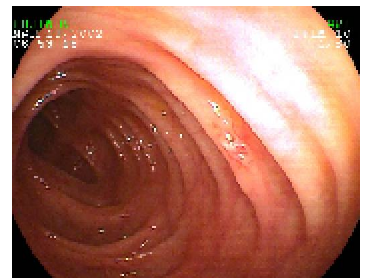
Retroflex view
 Anus



Sigmoid



Ileocecal valve
 Terminal ileum



Post polypectomy
 Mid-Transverse

John Smith, MD